



Sinusitis in children: the importance of diagnosis and treatment

KAYSE M. SHRUM, DO
STANLEY E. GROGG, DO
PHILLIP BARTON, MD
HARRIET H. SHAW, DO
ROBIN R. DYER, DO

The complications from untreated sinusitis in a 10-month-old male infant, though at the more severe end of the spectrum, brings to light the importance of diagnosis and treatment even in the very young patient. Acute sinusitis should be diagnosed using established guidelines. Appropriate pharmacologic and osteopathic manipulative treatment should be initiated on diagnosis. Initial antibiotic therapy is a 14-day course of amoxicillin. If the sinusitis fails to resolve, a trial of a second-line antibiotic should be considered. The use of adjunctive medications such as antihistamines, decongestants, and nasal steroids remains controversial. If the patient fails maximal medical therapy, a computed tomography scan and referral to an otolaryngologist for possible surgical intervention should be considered.

(Key words: sinusitis, pediatrics, rhinorrhea, *Hemophilus influenzae*, upper respiratory tract infection)

The diagnosis of sinusitis is one made with reluctance in the pediatric population. The complaint of rhinorrhea and cough is a common one attended by pediatricians and other primary care physicians. Viral respiratory tract infections are diagnosed daily in many infants and children. It is important, however, to determine which of these patients have had such infections progress to sinusitis and consequently require more aggressive therapy. Untreated sinusitis can lead to

serious and sometimes life-threatening complications, as underscored by the following case presentation in an infant who was treated for 2 months for viral upper respiratory tract infection and in whom nontypable *Hemophilus influenzae* meningitis developed.

Case presentation

A 10-month-old white boy was seen by his pediatrician on May 1 because of a 48-hour history of a 104°F temperature and febrile seizures. His only other symptoms at that time were greenish rhinorrhea and cough, which his mother reported had been present with intermittent fever for approximately 2 months. His pediatrician had seen him several times during the preceding 2 months for these symptoms. His mother was told that the child had a viral upper respiratory tract infection and to treat it symptomatically and it would eventually run its course. No radiographs or laboratory tests were done before May 1.

On May 1, a complete blood cell

count was within normal limits. Blood cultures were obtained from two sites. The next day, the child returned with the additional symptoms of vomiting and lethargy. The febrile seizures had persisted as well. The microbiology laboratory reported that the blood cultures drawn the previous day were positive for gram-negative rods. Lumbar puncture at that time was also positive for gram-negative rods on Gram's stain. Cefotaxime was administered intravenously. At physical examination, the patient was in a toxic condition and rapidly becoming obtunded. He was transported by helicopter to a pediatric intensive care unit. He became completely obtunded during the flight and required endotracheal intubation.

A repeated lumbar puncture revealed the following values: glucose, 1 mg/dL (normal, 50 to 80 mg/dL); protein, 187 mg/dL (normal, 15 to 45 mg/dL); white blood cells (WBCs), 1035/mm³ with 90% neutrophils and 10% monocytes; red blood cells (RBCs), 235/mm³. Gram-negative bacteria were present. Bacterial antigen profile of urine was negative. A complete blood cell count revealed 7.4 million/mm³ WBCs, with 75% neutrophils, 12% lymphocytes, 6% monocytes, and 1% eosinophils. A computerized tomography (CT) scan of the head was done. The radiologist reported that the CT scan revealed a right subdural low-density fluid collection with adjacent meningeal enhancement in the right temporal region, indicating meningitis with encephalitis. Opacification of the maxillary sinuses and some ethmoid air cells were present, indicating a previously undiagnosed sinusitis.

The initial blood culture and spinal fluid from both institutions grew out nontypable *H influenzae*. No evidence of a skull fracture, old or new, was ever identified on the CT scan. The mother denied any history of head trauma. Although the meningitis cannot be conclusively attributed to the untreated sinusitis, the nontypable *H influenzae* and the complications that followed would appear to be the culprit as all other reasonable etiologies were ruled out.

Dr Shrum is a resident in pediatrics at Tulsa Regional Medical Center, Tulsa, Okla; Dr Grogg is an associate professor of pediatrics, Oklahoma State University College of Osteopathic Medicine (OSU-COM); Dr Barton is a clinical associate professor of pediatrics, University of Oklahoma School of Medicine, Tulsa; and codirector of the Pediatric Intensive Care Unit, Children's Hospital at Saint Francis; Dr Shaw is a clinical professor of family medicine, OSU-COM; and Dr Dyer is a clinical assistant professor of family medicine, OSU-COM.

Correspondence to Stanley E. Grogg, DO, Associate Professor of Pediatrics, OSU-COM, 3345 S Harvard Ave, Suite 200, Tulsa, OK 74105.

E-mail: travelok@aol.com

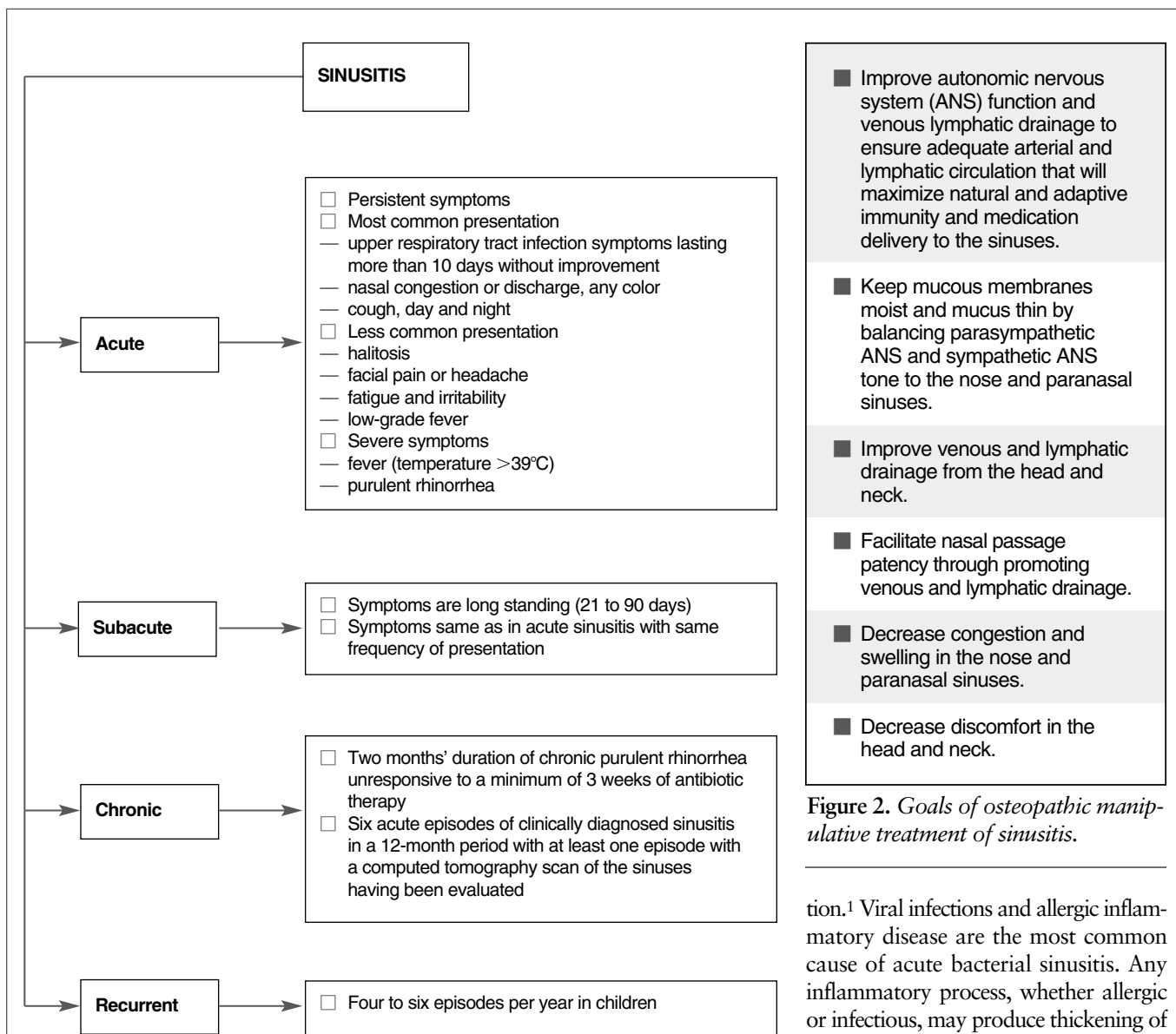


Figure 1. Guidelines for the diagnosis and treatment of sinusitis.

Figure 2. Goals of osteopathic manipulative treatment of sinusitis.

Anatomy

All paranasal sinuses develop as out-pouchings of the nasal mucosa. The development of the maxillary and ethmoid sinuses begins during the third month of gestation, and these sinuses are usually present, but small, at birth. The maxillary sinuses gradually enlarge during childhood and ultimately reach a capacity of 15 mL. The frontal and sphenoid sinuses begin to form about the age of 3 years, but they are rudimentary until age 5 or 6 years. Frontal sinus development is variable. Frontal sinuses may be

symmetric, hypoplastic, or may not form at all. The frontal, maxillary, and anterior ethmoid air cells drain to the middle meatus. The sphenoid and posterior ethmoid air cells open in the superior meatus. The paranasal sinuses are lined with ciliated epithelium. Drainage of the maxillary sinus is dependent on ciliary motion.

Pathophysiology

Any disease state or mechanical process that obstructs the ostia or decreases ciliary function places the sinus at risk for infec-

tion.¹ Viral infections and allergic inflammatory disease are the most common cause of acute bacterial sinusitis. Any inflammatory process, whether allergic or infectious, may produce thickening of the nasal and sinus mucosa, with capillary dilation and acute inflammatory exudate.¹ The resulting edema leads to ostial obstruction, pooling of sinus secretions, and secondary bacterial infection. The most common microorganisms in acute, subacute, and untreated chronic sinusitis are *Streptococcus pneumoniae*, *Moraxella catarrhalis*, and nontypable *H influenzae*. In chronic sinusitis, especially if it is previously treated or of long standing, anaerobes and *Staphylococcus aureus* are involved more frequently.

Diagnosis

Although the case presented is at the more severe end of the spectrum of complications of untreated sinusitis, it

Table
Antibiotics for Treatment of Children With Sinusitis

Antibiotic*	Dosage (mg/kg/d)	Comment
■ First-level		
<input type="checkbox"/> Amoxicillin (numerous brands and generic)	80 to 100 in divided doses every 12 hours	Low cost, palatable, safe, some bacterial resistance
<input type="checkbox"/> Sulfamethoxazole/trimethoprim (Septra, Bactrim, generic)	40/8 in divided doses every 12 hours	Low cost, rash, gastrointestinal distress, group A β -hemolytic streptococci and some pneumococcal resistance
<input type="checkbox"/> Erythromycin ethylsuccinate/sulfisoxazole acetyl (Pediazole, Eryzole)	50/150 in divided doses every 6 hours	Low cost, gastrointestinal symptoms, rash, four-times-a-day dosing
■ Second-level		
<input type="checkbox"/> Amoxicillin/clavulanate potassium (Augmentin)	40/10 in divided doses every 12 hours	Diarrhea, gastrointestinal distress, efficacious for most bacteria
<input type="checkbox"/> Cefaclor (Ceclor)	40 in divided doses every 8 hours	Hypersensitivity reaction, some bacterial resistance
<input type="checkbox"/> Cefixime (Suprax)	8 every 24 hours	Some pneumococcal resistance
<input type="checkbox"/> Cefpodoxime proxetil (Vantin)	10 in divided doses every 8 hours	Covers pneumococci, taste is objectional to some children
<input type="checkbox"/> Cefprozil (Cefzil)	30 in divided doses every 12 hours	Less activity against β -lactamase-positive organisms
<input type="checkbox"/> Cefuroxime (Zinacef) [†]	40 to 100 in divided doses every 8 hours;	Good spectrum of coverage, marginal taste
<input type="checkbox"/> Cefuroxime axetil (Ceftin) [‡]	30 in divided doses every 12 hours	Good spectrum of coverage
<input type="checkbox"/> Loracarbef (Lorabid)	30 every 12 hours	Spectrum of coverage like that of second-generation cephalosporin
<input type="checkbox"/> Azithromycin (Zithromax)	10 once a day on day 1, 5 every 24 hours on days 2 through 5	Uncommon gastrointestinal symptoms, good spectrum of coverage
<input type="checkbox"/> Clarithromycin (Biaxin)	15 every 12 hours	Good spectrum of coverage, gastrointestinal symptoms, avoidance during pregnancy, poor taste, interaction with astemizole and terfenadine [§]
<input type="checkbox"/> Cefdinir (Omnicef)	14 once a day	Good taste, once-daily dosage

*Generic names with brand names in parentheses.
[†]For intramuscular and intravenous administration.
[‡]For oral administration.
[§]Removed from marketplace by manufacturer.

should certainly cause a practitioner to consider treating clinical sinusitis even in the very young patient. Sinusitis should be diagnosed and treated using the established guidelines as delineated in *Figure 1*.

Treatment

The goals of treatment of sinusitis are to reduce tissue edema, facilitate drainage, and control infection. Osteopathic physicians can use osteopathic manipulative treatment (OMT) and antibi-

otics to reach these goals (*Figure 2, Table*). Following established guidelines for the diagnosis and treatment of sinusitis ensures judicious use of antibiotics in the face of growing antimicrobial resistance.

- Do an occipitoatlantal decompression.
- Do rib raising (Figure 4).
- Do lymphatic pump procedures (Figure 5).
- Do articular myofascial technique or indirect myofascial technique (or both) to the cervical, thoracic, and lumbar spine (described in text).
- Do mandibular drainage and cervical soft tissue technique (Figure 6).

Precaution: Always evaluate the condition of the patient before proceeding with any of these procedures. There may be times when some or all of these procedures may be contraindicated or unduly difficult because of a child's uncooperativeness. Clinical judgment should be used at all times. Refrain from using any manual medicine procedure that requires considerable force on the pediatric patient.

Figure 3. Protocol for treating sinusitis in the pediatric patient.

Pharmacologic treatment

First-line therapy for acute sinusitis should include amoxicillin (80 mg/kg/d to 100 mg/kg/d in divided doses every 12 hours) for 14 days and OMT. The following are indications for the initiation of a second-line antibiotic (Table):

- no clinical response after 48 to 72 hours of initiating therapy;
- a clinical history of early recurrences or treatment failures of acute sinusitis after amoxicillin therapy;
- a patient who has had frequent courses of multiple antibiotics;
- a high incidence of β -lactamase-producing organisms in the community; and
- failure to respond after 14 days of amoxicillin therapy.

Decongestants, antihistamines, and nasal corticosteroids

The effectiveness of topical deconges-

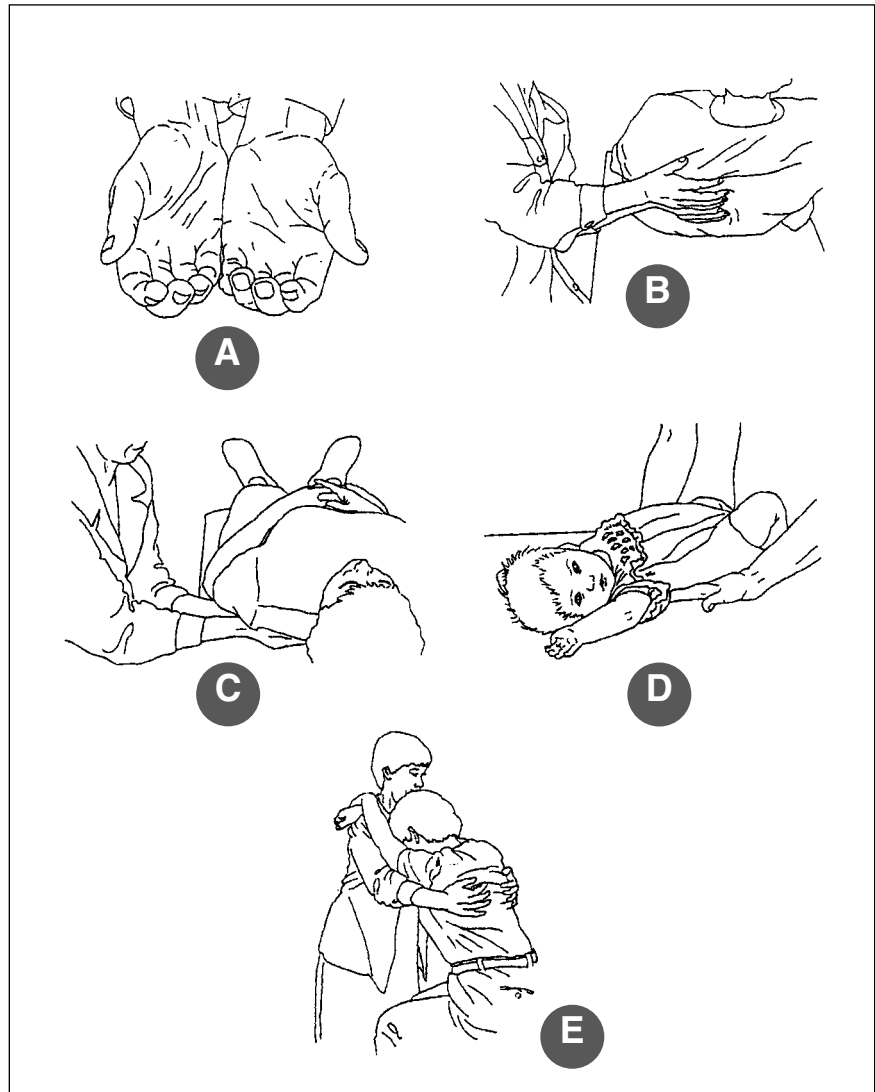


Figure 4. Rib raising treatment. A: hand position; B: hand placement; C: lifting rib angles (with patient supine); D: rib raising in infants and small children; E: rib raising with patient seated. (Illustrations courtesy of Kenneth E. Graham, DO.)

tants and antihistamines in patients with sinusitis is still controversial. In patients with an allergic component, antihistamines may have a preventive role. In the treatment of sinusitis, however, antihistamines may dry sinus secretions, decreasing mucus clearance from the sinus cavity and should not be used routinely. Topical decongestants reduce edema, improve osteal drainage, and provide symptomatic relief. However, topical decongestants can cause ciliary stasis, thereby inhibiting ciliary motion and clearance of infected material. Sys-

temic decongestants are not typically indicated in the treatment of sinusitis in children.

Topical corticosteroids may be an option to reduce tissue edema and improve sinus drainage if the initial course of antibiotic therapy has failed. Both hypertonic saline solution² and topical corticosteroids^{3,4} have been demonstrated to be effective and may decrease the duration of the infection and decrease the number of future episodes. The efficacy of nasal corticosteroids in the inflammatory response in sinusitis is still

uncertain. These agents are not indicated as first-line therapy.

Osteopathic manipulative treatment

The following anatomic and physiologic considerations should guide administration of OMT to the pediatric patient with sinusitis:

■ Drainage of sinus cavities is not only accomplished by gravity, but it also requires normal bone motion, functional ciliary motion, and free flow of mucus. Ethmoid and maxillary sinuses are present at birth; frontal and sphenoid sinuses do not appear until age 8 to 10 years. Compression of the anterior cranium during delivery or from postnatal trauma can encroach on the size of the sinus cavities and interfere with normal drainage.

■ Compression of the temporal and sphenoid bones can also affect the sphenopalatine ganglion, which carries both the parasympathetic and sympathetic autonomic nerves to the nose and the sinuses.

■ Compression of the cranial base and occipitoatlantal region can affect the tone of the parasympathetic autonomic nervous system via the vagus nerve as it exits through the jugular foramen and can obstruct venous outflow, thus contributing to swelling of the tissues of the nasopharynx and face.

■ Innervation of the sympathetic autonomic nervous system to the head arises from the upper thoracic vertebrae, then travels through the superior, middle, and inferior cervical ganglia, which lie in the deep fascia of the neck.

■ Somatic dysfunction in the neck and upper thorax can affect the thoracic outlet by somatovisceral reflexes, as well as by direct compression of the venous and lymphoid drainage of the head.²

Figure 3 outlines the protocol for OMT for sinusitis in the pediatric patient.

A technique that is especially useful in children is segmental myofascial release of the upper thoracic and cervical spine, because it does not require cooperation. It applies the skills learned with counterstrain, articulation, translation, myofascial, and cranial techniques,

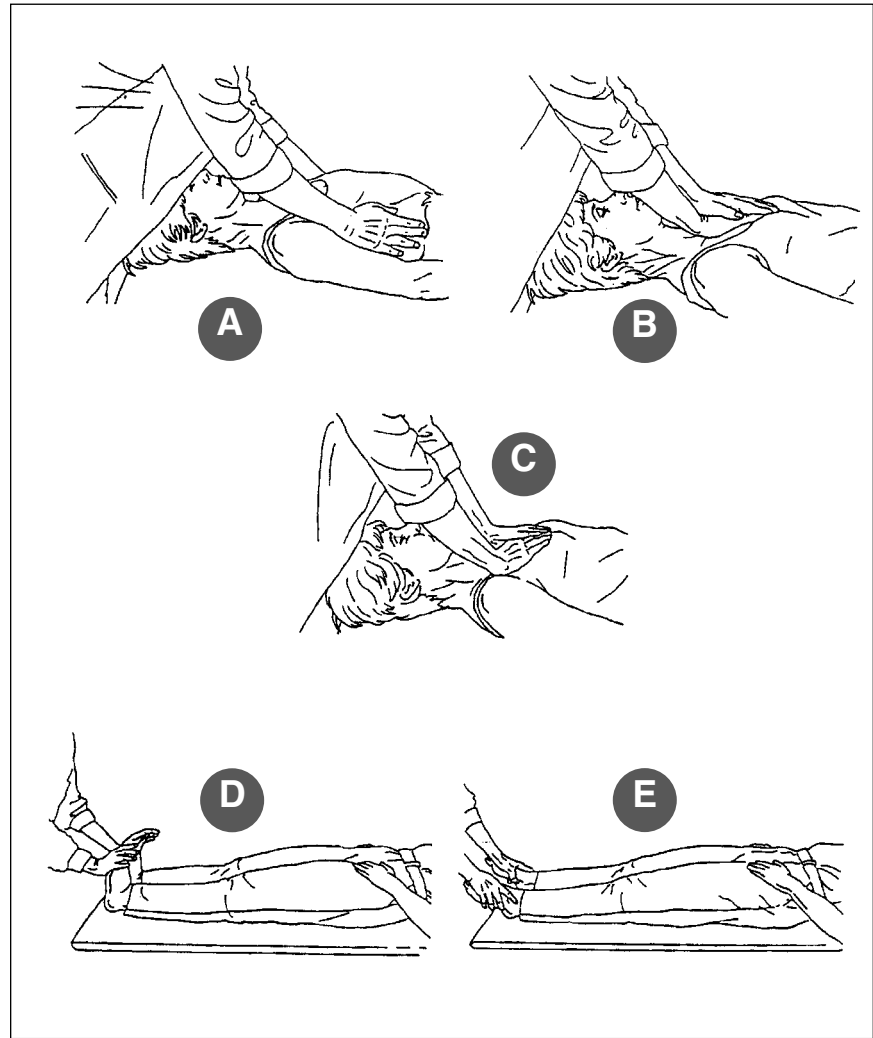


Figure 5. Lymphatic pump treatment. A: hand placement; B: anterior chest wall (sternal) pump; C: anterior chest wall pump; D: pedal pump (dorsiflexion); E: pedal pump (plantar flexion). (Illustrations courtesy of Kenneth E. Graham, DO.)

depending on the operator's skill level.

With the patient lying supine, slide the forearms, palms up, under the upper thorax on each side of the spine. Feel the tissues of the upper ribs. While holding an area of three to four posterior ribs, add a little compression between the thumbs and fourth and fifth fingers, and medially toward the spine; feel which way the tissues will "give" or will allow you to move them. This is an indirect technique. Feel this movement in external rotation, sidebending, flexion, or extension. The sides often tend to move reciprocally in relation to each other. When you reach a point of balanced

membranous tension, hold that. You will find that the point of balance is dynamic and may call you to move to reach it again. If you get to an area that seems "stuck," try a little articulation (for example, move the tissues the way that they do not want to go), more compression, or distraction.

The movements may be very subtle. At the release, you may feel a softening of the tissues, or the primary respiratory mechanism, with or without a still point. The technique may also be done one side at a time, with the opposite hand compressing from the anterior aspect of the thorax. Again, the motions tend to be

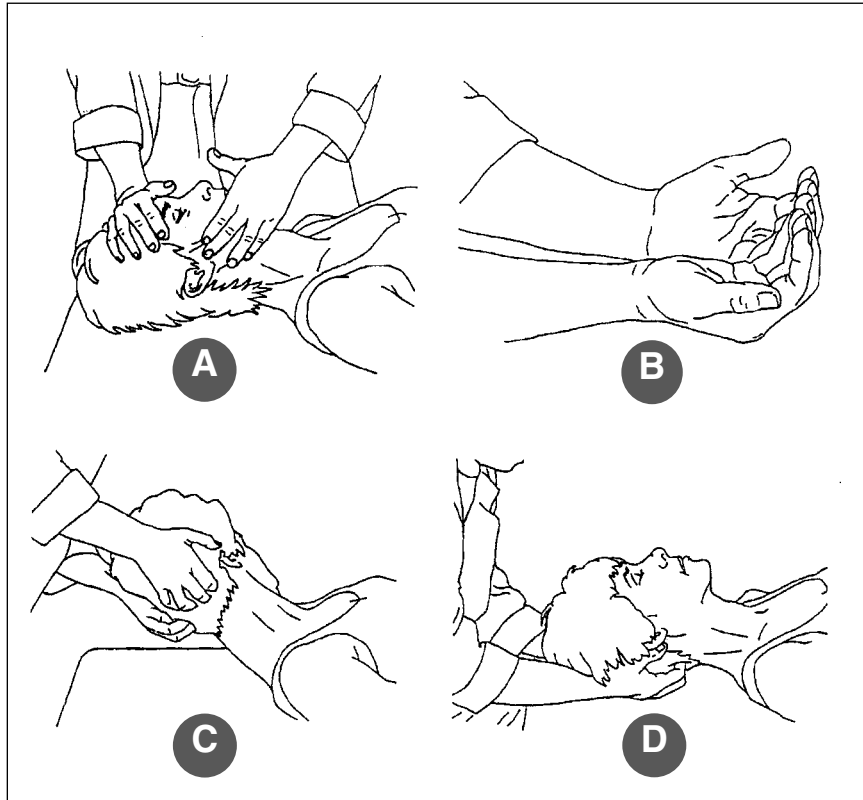


Figure 6. Cervical soft tissue technique. A: mandibular drainage; B: inhibitory pressure (hand position); C: inhibitory pressure (hand placement); D: inhibitory pressure. (Illustrations courtesy of Kenneth E. Graham, DO.)

reciprocal (for example, up in front, down in back, etc).

To administer specific segmental releases, move the fingers more medially along the paraspinus musculature so the tips are facing each other and the third and fourth fingers straddle above and below a specific segment. Motion test that segment in all three planes, and encourage the movement in the direction it wants to go, holding at a point of balanced membranous tension. Some experimentation may be necessary to achieve complete release.

Move the fingers up to the next higher segment and repeat the process. Again, you may find it useful to move one hand on top of the sternum and apply compression, with the posterior hand controlling the specific vertebral segment between the thumb and first two fingers.

This process can be applied to the entire upper thoracic and cervical spine.

On the cervical spine, sidebending is achieved by translation. The segment can be treated with a combination of directly with articulation and indirectly as described. Sometimes, you will feel a pulsation in the region associated with the release, but this is not to be considered the end of the treatment. When the tissues are "done," they will soften and allow you to return to a neutral position or you will feel the primary respiratory mechanism prominently.

Comment

If the patient shows signs of improvement but symptoms have not resolved, use of the antibiotic and OMT should be continued for an additional 7 to 10 days. The diagnosis of subacute sinusitis should be considered if the patient fails to respond to a second course of therapy. Therapy may be discontinued after the patient is asymptomatic for 3 to 5 days; however, if the patient should

become worse or acutely ill during the course of therapy, a CT scan and referral to an otolaryngologist should be considered.

Acknowledgment

The authors wish to thank Kenneth E. Graham, DO, clinical associate professor of family medicine, Oklahoma State University College of Osteopathic Medicine, Tulsa, for his contribution in the preparation of this article.

Reference

1. Lazar RH, Younis RT. The current management of sinusitis in children. *Clin Pediatr (Phila)* 1992;31(1):30-36.
2. Shoseyov D, Bibi H, Shai P, Shoseyov N, Shazberg G, Hurvitz H. Treatment with hypertonic saline versus normal saline nasal wash of pediatric chronic sinusitis. *J Allergy Clin Immunol* 1998;101:602-605.
3. Barlan IB, Erkan E, Bakir M, Berrak S, Basaran MM. Intranasal budesonide spray as an adjunct to oral antibiotic therapy for acute sinusitis in children. *Ann Allergy Asthma Immunol* 1997;78:598-601.
4. Yilmaz G, Varan B, Yilmaz T, Gurakan B. Intranasal budesonide spray as an adjunct to oral antibiotic therapy for acute sinusitis in children. *Eur Arch Otorhinolaryngol* 2000;257:256-259.

Bibliography

- Blumer J. Clinical perspectives on sinusitis and otitis media. *Pediatr Infect Dis J* 1998;17(8 Suppl):S68-S72.
- Chan KH, Winslow CO, Levin MJ, Asburg MJ, Shira JE. Clinical practice guidelines for the management of chronic sinusitis in children. *Otolaryngol Head Neck Surg* 1999;120:328-334.
- Drettner B. Pathophysiology of paranasal sinuses with clinical implications. *Clin Otolaryngol* 1980;5:277-284.
- Herrod HG. Immunologic considerations in the child with recurrent or persistent sinusitis. *Allergy Asthma Proc* 1997;18:145-148.
- Hopp R, Cooperstock M. Medical management of sinusitis in pediatric patients. *Curr Probl Pediatr* 1997;27:178-186.
- Incaudo GA, Wooding LG. diagnosis and treatment of acute and subacute sinusitis in children and adults. *Clin Rev Allergy Immunol* 1998;16:157-204.
- Isaacson G. Sinusitis in childhood. *Pediatr Clin North Am* 1996;43:1297-1318.
- Jones NS. Current concepts in the management of paediatric rhinosinusitis. *J Laryngol Otol* 1999;113:1-9.
- Newton DA. Sinusitis in children and adolescents. *Prim Care* 1996;23:701-717.
- Wagner W. Changing diagnostic and treatment strategies for chronic sinusitis. *Cleve Clin J Med* 1996;63:396-405.
- Wald R, Ellen R. Diagnosis and management of acute sinusitis. *Pediatric Annals* 1998;17:629-638.