
CLINICAL COMMENTARY DEFORMITY OR DYSFUNCTION? OSTEOPATHIC MANIPULATION OF THE IDIOPATHIC CAVUS FOOT: A CLINICAL SUGGESTION.

Christopher Kevin Wong, PT, PhD, OCS^a
Adi Gidali, PT, DPT^b
Valerie Harris, PT, DPT^c

ABSTRACT

Observed gait abnormalities are often related to a variety of foot deformities such as the cavus foot, also known as pes cavus, cavovarus, uncompensated varus, and the high arched foot. When gait abnormalities related to cavus foot deformities produce symptoms or contribute to dysfunctional movement of the lower extremity, foot orthotics are commonly used to accommodate the deformity and optimize the function of the lower extremity. In more severe cases, surgical intervention is common. Hypomobility of the many joints of the foot and ankle may be mistaken as an idiopathic cavus foot deformity. As for any other limb segment suspected of musculoskeletal dysfunction, it is suggested that joint mobility testing and mobilization, if indicated, be attempted on the foot and ankle joints before assuming the presence of a bony cavus deformity. The purpose of this clinical suggestion is to describe the use of osteopathic manipulations of the foot and ankle in the context of an illustrative case of bilateral idiopathic cavus feet to demonstrate that apparent foot deformities may actually be joint hypomobility dysfunctions.

Keywords: manipulation, cavus foot, midfoot

CORRESPONDENCE

Christopher Kevin Wong, PT, PhD, OCS
Program in Physical Therapy,
Columbia University
710 West 168th Street
NY, NY 10032
Telephone: 212-305-0683
Fax: 212-305-4569
e-mail: ckw7@columbia.edu

The Institutional Review Board of Columbia University Medical Center, New York, NY reviewed this single case report and found it not to be research on human subjects and thus did not require approval.

^a Columbia University
New York, NY

^b Thrive Integrated Physical Therapy
New York, NY

^c New York, NY

PROBLEM

Foot deformities are often associated with gait abnormalities that may contribute to dysfunction or pathology. One such deformity, the high arched or idiopathic cavus foot, has been associated with peroneal tendonopathy,¹ lateral ankle sprains and instability,^{2,3} ankle arthritis,⁴ metatarsalgia or fracture,⁵ and up the kinetic chain to the knee,⁶ hip,⁷ and back.⁸ Characterized by a high medial longitudinal arch, plantarflexed first ray, claw toes, and callous over the 5th metatarsal base, the cavus foot is considered a varus foot deformity involving both the rear- and forefoot.^{5,9,10} The cavus foot ranges in severity from clubfoot to mild variants referred to as pes cavus or subtle cavus foot, and can be fixed or flexible.^{5,9} The fixed or flexible nature of the deformity is determined by whether the rearfoot joints are grossly mobile enough to compensate for the varus deformities to place the foot in a plantigrade position.^{10,11,12} Fixed varus deformities, isolated or both rear- and forefoot combined, are also referred to as uncompensated, while the flexible type are referred to as compensated.

Cavus foot deformities may lead to gait abnormalities that generate local or more proximal leg symptoms and dysfunction, and may require treatment.^{13,14} Limited evidence supports the use of orthotics in cases of idiopathic cavus feet.^{13,15,16} For many cases of idiopathic cavus foot, non-operative care including stretching, shoe modification, and foot orthotics have been recommended, but often been found to be inadequate.^{5,9} When non-operative care is not successful, a variety of surgical procedures can correct the bony cavus deformity.^{3,4,5,9,17}

An idiopathic cavus foot may exist due to hypomobility of any combination of the many joints in the foot and ankle. Joint manipulation to the hypomobile foot or ankle joints, followed by soft tissue surgery and serial casting as described by Ponseti and Smoley,¹⁸ has become common in pediatric cases of idiopathic clubfoot. Compared to manipulation and surgical arthrodesis, the

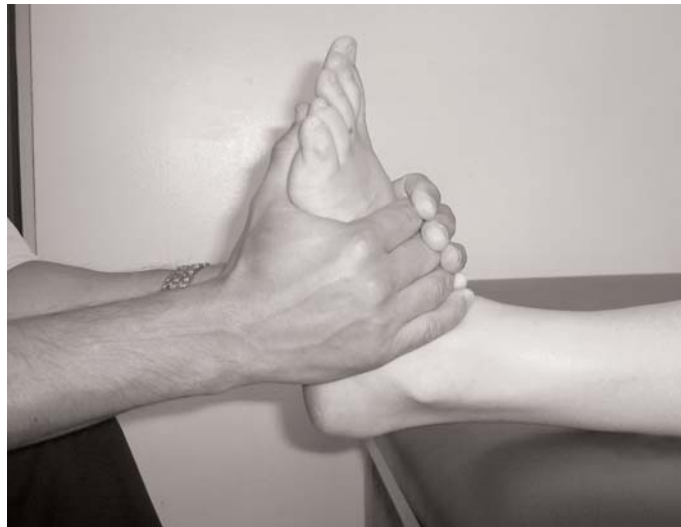

Figure 1: Talocrural joint separation high velocity low amplitude thrust (HVLAT). With patient in supine, operator gently positions the ankle in slight dorsiflexion and grasps dorsal foot with both hands: thumbs on plantar aspect and 5th fingers over anterior talus. The operator applies an axial distraction force with HVLAT. Tibia can be stabilized to protect proximal joints.

Ponseti and Smoley¹⁸ approach has resulted in greater parental satisfaction and ankle range-of-motion (ROM) outcomes.¹⁹ No known reports of joint manipulation changing the architecture of the idiopathic uncompensated varus foot in adults exist. This paper illustrates several osteopathic manipulations addressing specific joint hypomobility in the idiopathic cavus foot to demonstrate the importance of mobilizing specific hypomobile joints before determining that a fixed foot deformity exists and requires other treatment.

SOLUTION

Some cases of idiopathic cavus foot may be amenable to osteopathic manipulation, a term used here to refer to direct joint mobilization (grade I-V), and indirect mobilization via Strain Counterstrain. When specific joint mobility assessments of the foot and ankle joints indicate hypomobility, it is suggested that osteopathic manipulation be attempted. Clinically, the selection of appropriate techniques will depend on assessment of the individual. In this case, 5 techniques were applied: 1) high velocity low amplitude thrust (HVLAT) talocrural joint separation, 2) Strain Counterstrain (SCS) for the lateral calcaneus (LCA), 3) HVLAT of the navicular, 4) mobilizations with movement (MWM) of the cuboid, and 5) MWM of the first metatarsal phalangeal (MTP) joint.

Limited evidence exists to support some of these techniques, while other techniques have not been reported in the literature. Talocrural joint separation with HVLAT has been described²⁰ and used to increase ankle dorsiflexion in cases of equinus²¹, diabetes²², plantar fasciitis²³, and ankle sprains (Figure 1).²⁴⁻²⁷ Jones²⁸ introduced SCS and described the application SCS for the lateral calcaneus, though not specifically for increasing rearfoot eversion as in this case (Figure 2). A HVLAT applied to the dorsal navicular for increased mid-foot pronation has not been reported in the literature (Figure 3). Mobilizations with

movement (MWM) were introduced by Mulligan,²⁹ and ankle MWM have been reported to increase ankle dorsiflexion.^{30,31} Open chain manipulation of the cuboid with the ankle plantarflexed for ankle sprains has been reported, but closed chain MWM of the cuboid to increase pronation with midfoot plantarflexion has not been described (Figure 4).³² MWM of the MTP joint to increase dorsiflexion after heel-off during gait (Figure 5) has also not been reported in the literature.

USE IN PHYSICAL THERAPY

The subject is a 27-year-old woman who presented with bilateral idiopathic cavus feet. Both feet appeared to have uncompensated rear- and forefoot varus deformities such that her first rays were atypically not plantarflexed and she bore no weight on the medial side of her foot in standing and walking. The subject's mother, who reportedly has similar but less severe cavus feet, reported that the subject's feet had always appeared the same since beginning to walk at eight months old. The subject's parents sought medical intervention at two years of age to address her bow-legged and hyper-lordotic posture. The physician assured them, however, that any deformity would correct as she developed without treatment or orthoses. Although the subject always walked on the lateral border of both feet, she had no other medical issues other than an ankle sprain from a car accident when nine years old. She never limited her activities and as an adult has exercised four to

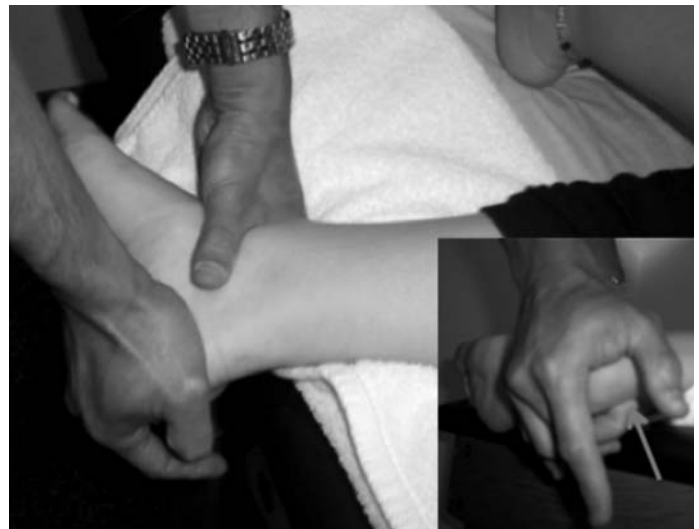

Figure 2: Strain Counterstrain for the lateral calcaneus tender point (LCA). With patient in side lying and LCA monitored with the operator's right 3rd digit (inset), right hand directs force to the medial posterior calcaneus for 90 seconds while left hand supports anterior talus.

five times per week. Over the past five years, however, the subject reported insidious low back pain and bilateral hip pain ranging in intensity from three to seven on a scale with ten being the worst pain. She also reported bilateral clicking heel pain and overall discomfort in both feet. Pain on her left side had progressed in the past year leading her to consult a physical therapist.

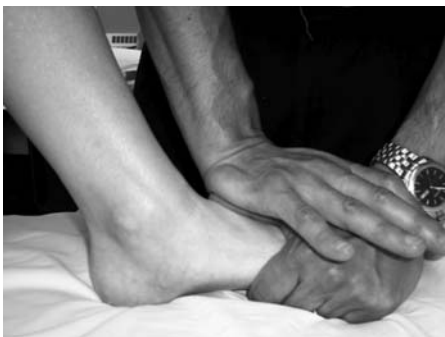

Figure 3: High velocity low amplitude thrust (HVLAT) applied to the dorsal navicular. With patient in hook lying, operator grasps medial metatarsals and pulls into dorsiflexion while left thumb rests on the superolateral border of the navicular. The operator applies a dorsal-plantar HVLAT with the hypothenar eminence of the right hand through the thumb to the navicular.

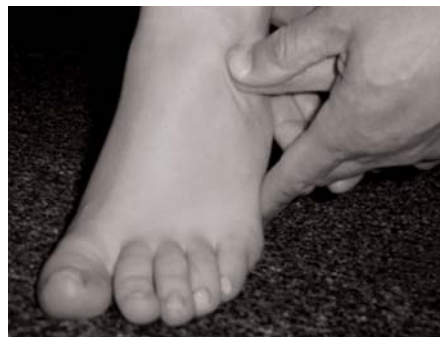

Figure 4: Mobilization with movement (MWM) of the cuboid. With patient seated, operators' thumbs deliver sustained pressure to the proximal medial cuboid to pronate the cuboid in frontal plane, as the patient plantarflexes at the ankle and mid-foot during a seated heel raise.

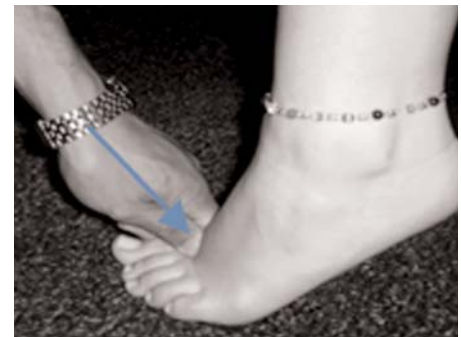

Figure 5: Mobilization with movement (MWM) of the 1st metatarsal phalangeal joint. With patient seated, operator's thumb and 2nd proximal interphalangeal joint deliver sustained pressure on the distal aspect of the metatarsal head at an oblique angle to facilitate plantar glide of the metatarsal head and metatarsal phalangeal dorsiflexion during seated heel raise.

At the time of consultation, the subject stood on the lateral borders of both feet with uncompensated cavus feet apparent. Her bilateral hip, knee, and ankle ROM were grossly normal except ankle dorsiflexion at approximately 10 degrees, rearfoot eversion less than neutral, and first MTP dorsiflexion at approximately 45 degrees. Mobility testing of the talocrural, subtalar, midtarsal, and first MTP joints revealed bilateral hypomobility throughout. Her gait was marked by a loud impact upon heel-strikes with lateral weight bearing throughout the stance phase. Pronation of the subtalar and midtarsal joints were insufficient for her feet to achieve medial plantigrade.

It was agreed upon to attempt to reduce the cavus foot architecture with osteopathic manipulation, starting with her right foot. Mortise separation with HVLAT increased

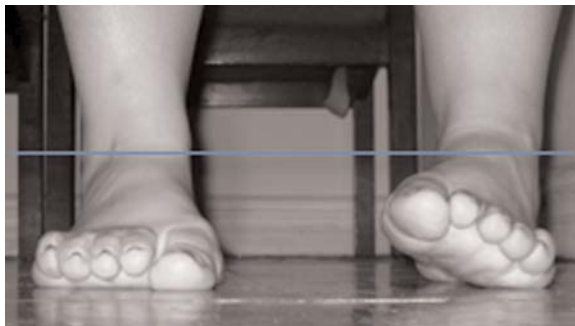

Figure 6: Anterior view after the subject's 1st consultation. Prior to intervention, the subject stood on the lateral borders of her feet with uncompensated cavus apparent. After osteopathic manipulation as described in this case study, her right foot achieved plantigrade. Note leg length discrepancy after unilateral correction.

ankle dorsiflexion by approximately 5 degrees. Strain Counterstrain for LCA resulted in rearfoot eversion past neutral, but did not alter the cavus shape of her foot. The HVLAT to the navicular resulted in dramatic lowering of her medial foot to plantigrade in standing, though she exhibited minimal first toe weight bearing during the terminal stance phase of gait. Closed chain MWM of the cuboid was used to increase midtarsal joint pronation and enhance medial weight bearing in both standing and gait. Closed chain MWM of the first MTP joint to increase dorsiflexion in terminal stance was applied once medial weight bearing was achieved. The net result was normalized standing posture and gait (Figures 6 & 7).

After the first consultation, a home exercise program was provided including ankle and hip stretching, active closed chain ankle and toe dorsiflexion, and unilateral bridging for hip strength. Between the first and second consultation, the subject experienced general leg soreness, periodic lateral ankle and medial knee pain after walking several blocks, increased pressure around the lateral malleolus, numbness and tingling at the distal lateral lower leg, and disruption of her balance experienced as a veering limp to the left and occasional trip on sidewalk cracks.

The manipulation sequence was repeated on her left foot at the second consultation, three weeks later, when her feet did not exhibit signs of cavus deformity (Figure 8), except for lateral claw toes due to residual soft tissue

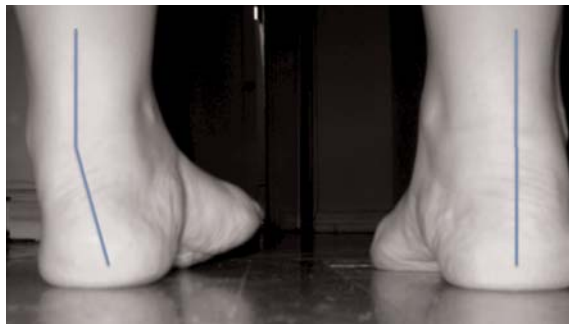

Figure 7: Posterior view after the subject's 1st consultation. Note the marked rearfoot varus alignment of the uncorrected left foot compared to the corrected right foot rearfoot alignment.

contracture (Figure 9). Her back, hip, knee, and heel pain were completely relieved. Her gait was normalized, and she reported quieter, more comfortable bilateral heel strike two weeks after the second consultation. However, occasional loss of balance to her left occurred when walking fast. Residual numbness and tingling extended from the anterior ankle proximally to the lower leg. In short, the apparent uncompensated cavus foot deformities were actually multi-joint hypomobility-related dysfunctions.

DISCUSSION

The foot and ankle complex includes many joints, all of which can become hypomobile independently or as a group. This case of idiopathic cavus foot corrected with osteopathic manipulation is presented to provoke the con-

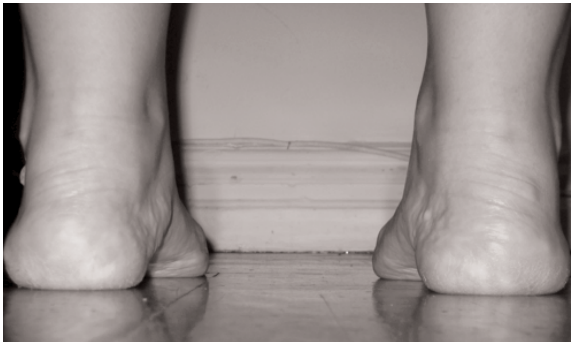

Figure 8: Posterior view after the subject's 2nd consultation. Note full weight bearing on the 1st metatarsal phalangeal joints of both feet after bilateral manipulation.

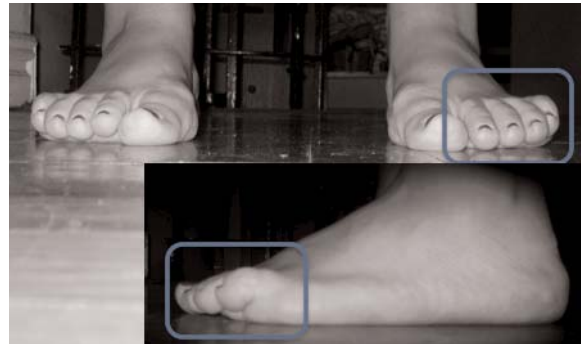


Figure 9: Anterior view of the subject's feet after 2nd consultation. Note residual lateral claw toes and lateral foot border hypertrophy (lateral view inset).

sideration of whether observed foot abnormalities are bony deformities or dysfunctional joint hypomobility. As in this case, some idiopathic cavus foot abnormalities may be corrected with osteopathic manipulation. The patient/client should be advised to prepare for potential post-treatment lower extremity discomfort. In cases of bilateral abnormalities, treatment of both feet on the same day can minimize asymmetry-related discomfort, although in this case scheduling precluded this approach. Before assuming the presence of immutable bony deformity that may require orthoses or surgery, clinicians are suggested to assess the specific joint mobility of all foot and ankle joints and mobilize if hypomobility is indicated.

REFERENCES

- Harris N, Stevens M. A cavovarus foot is a predisposing factor for rather than a result of peroneus longus tendinopathy. *Foot Ankle Int.* 2000;21:462-8.
- Larsen E, Angerman P. Association of ankle instability and foot deformity. *Acta Orthop Scand.* 1990;61:136-139.
- Vienne P, Schöniger R, Helmy N, et al. Hindfoot instability in cavovarus deformity: Static and dynamic balancing. *Foot Ankle Int.* 2007;28:96-102.
- Fortin PT, Guettler J, Manoli A 2nd. Idiopathic cavovarus and lateral ankle instability: Recognition and treatment implications relating to ankle arthritis. *Foot Ankle Int.* 2002;23:1031-7.
- Manoli A 2nd, Graham B. The subtle cavus foot, "the underpronator". *Foot Ankle Int.* 2005;26:256-263.
- Saxena AM, Haddad J. The effect of foot orthoses on patellofemoral pain syndrome. *J Am Podiatr Med Assoc.* 2003;93:264-271.
- Gross KD, Niu J, Zhang YQ, et al. Varus foot alignment and hip conditions in older adults. *Arthritis Rheum.* 2007; 56:2993-8.
- Builder MA, Marr SJ. Case history of a patient with low back pain and cavus feet. *J Am Podiatr Med Assoc.* 1980; 70:299-301.
- McCluskey WP, Lovell W, Cummings RJ. The cavovarus foot deformity: Etiology and management. *Clin Orthop Relat Res.* 1989;247:27-37.
- Marks RM. Midfoot and forefoot issues cavovarus foot: Assessment and treatment issues. *Foot Ankle Clin N Am.* 2005;13:229-2241.
- Coleman SS, Chesnut W. A simple test for hindfoot flexibility in the cavovarus foot. *Clin Orthop Relat Res.* 1977;123:60-2.
- Price BD, Price C. A simple demonstration of hindfoot flexibility in the cavovarus foot. *J Pediatr Orthop.* 1997; 17:18-9.
- Burns J, Crosbie J, Ouvrier R, et al. Effective orthotic therapy for the painful cavus foot: a randomized controlled trial. *J Am Podiatr Med Assoc.* 2006;96:205-11.
- Gross ML, Napoli R. Treatment of lower extremity injuries with orthotic shoe inserts. An overview. *Sports Med.* 1993; 15:66-70.
- Burns J, Landorf KB, Ryan MM, et al. Interventions for the prevention and treatment of pes cavus. *Cochrane Database of Systematic Reviews*, 2007, Issue 4.
- Geraci MC Jr, Brown W. Evidence-based treatment of hip and pelvic injuries in runners. *Phys Med Rehabil Clin N Am.* 2005;16:711-47.
- Klaue K. Planovalgus and cavovarus deformity of the hind foot: a functional approach to management. *J Bone Joint Surg Br.* 1977;79:892-5.

-
18. Ponseti IV, Smoley E. The classic: congenital clubfoot: the results of treatment. *Clin Orthop Relat Res.* 2009;467:1133-1145.
 19. Zwick EB, Krauss T, Maizen C, et al. Comparison of Ponseti versus surgical treatment for idiopathic clubfoot: a short-term preliminary report. *Clin Orthop Relat Res.* 2009;467:2668-76.
 20. Lawrence DJ. Chiropractic manipulation for the foot: diversified chiropractic techniques. *Man Ther.* 2001;6:66-71.
 21. Dananberg HJ. Manipulation of the ankle as a method of treatment for ankle and foot pain. *J Am Podiatr Med Assoc.* 2004;94:395-399.
 22. Murphy DR. Diagnosis and manipulative treatment in diabetic polyneuropathy and its relation to intertarsal joint dysfunction. *J Manipulative Physiol Ther.* 1994;17:29-37.
 23. Dimou ES. A randomized, controlled trial (with blinded observer) of chiropractic manipulation and Achilles stretching vs. orthotics for the treatment of plantar fasciitis. *J Am Chiro Assoc.* 2004;41:32-42.
 24. Pellow JE, Brantingham J. The efficacy of adjusting the ankle in the treatment of subacute and chronic grade I and grade II ankle inversion sprains. *J Manipulative Physiol Ther.* 2001;24:17-24.
 25. Lopez-Rodriguez S, de-las-Peñas CF, Albuquerque-Sendin F, et al. Immediate effects on manipulation of the talocrural joint on stabilometry and baropodometry in patients with ankle sprain. *J Manipulative Physiol Ther.* 2007;30:186-192.
 26. Kohne E, Jones A, Korporaal C, et al. A prospective, single-blinded, randomized, controlled clinical trial of the effects of manipulation on proprioception and ankle dorsiflexion in chronic recurrent ankle sprain. *J Am Chiro Assoc.* 2007;44:7-17.
 27. Whitman JM, Cleland JA, Mintken PE, et al. Predicting short-term response to thrust and non-thrust manipulation and exercise in patients post inversion ankle sprain. *J Orthop Sports Phys Ther.* 2009;39:188-200.
 28. Jones LH. Foot treatment without hand trauma. *J Am Osteopath Assoc.* 1973;73:481-9.
 29. Vicenzino B, Paungmali A, Teys P. Mulligan's mobilization-with-movement, positional faults and pain relief: current concepts from a critical review of literature. *Man Ther.* 2007;12:98-108.
 30. Vicenzino B, Branjerdporn M, Teys P, et al. Initial changes in posterior talar glide and dorsiflexion of the ankle after mobilization with movement in individuals with recurrent ankle sprain. *J Orthop Sports Phys Ther.* 2006;36:464-71.
 31. Collins N, Teys P, Vicenzino B. The initial effects of a Mulligan's mobilization with movement technique on dorsiflexion and pain in subacute ankle sprains. *Man Ther.* 2004;9:77-82.
 32. Jennings J, Davies G. Treatment of cuboid syndrome secondary to lateral ankle sprains: A case series. *J Orthop Sports Phys Ther.* 2005;35:409-415.